



Eurasia Specialized Veterinary Publication

International Journal of Veterinary Research and Allied Science

2021, Volume 1, Issue 1, Page No: 19-31

Copyright CC BY-NC-SA 4.0

Available online at: www.esvpub.com/

Evaluation of *Urtica dioica* Extract as a Protective Agent against Hepatic and Renal Toxicity Induced by Insecticides

Mongi Saoudi^{1*}, Fatma Rahmouni², Malek El Aroui¹, Mariem Boudaya³, Kamel Jamoussi³, Choumouss Kallel⁴, Abdelfattah El Feki¹

¹Animal Physiology Laboratory, Faculty of Sciences of Sfax, University of Sfax, Tunisia.

²Histo-Embryology and Cytogenetic Laboratory, Medicine Faculty of Sfax, University of Sfax, Tunisia.

³Biochemistry Laboratory, Hospital Hedi Chaker of Sfax, Tunisia.

⁴Hematology Laboratory, Hospital Habib Bourguiba of Sfax, Tunisia.

*E-mail ✉ mongifss@yahoo.fr

ABSTRACT

This study aimed to explore the protective potential of *Urtica dioica* (*U. dioica*) against liver and kidney damage caused by combined exposure to the insecticides deltamethrin (DLM) and chlorpyrifos (CPF). Five experimental groups of rats were established: a control group, a group exposed to the DLM/CPF insecticide mixture, a group receiving a combination of vitamins C and E alongside the DLM/CPF mixture, a group administered an aqueous extract of *U. dioica* and a group treated with both the extract of *U. dioica* and the mixture of DLM/CPF. Analysis showed that *U. dioica* contained high levels of polyphenols (712.37 µg/g GAE/mg of dry plant). Exposure to DLM/CPF resulted in impaired red blood cell (RBC) count, hemoglobin (HB), and hematocrit (Ht), as well as increased levels of aspartate aminotransferase (ASAT), alanine aminotransferase (ALAT), lactate dehydrogenase (LDH), alkaline phosphatase (ALP), creatinine, urea, and uric acid. In addition, significant increases in thiobarbituric acid reactive substances (TBARS), conjugated dienes (CD), protein carbonyls (CP), and oxidation protein products (AOPP) were reported. The findings suggest that *U. dioica* has therapeutic properties against certain health issues, and exhibits significant antioxidant and antiradical activities.

Keywords: Antioxidant, *U. dioica*, Toxicity, Deltamethrin, Chlorpyrifos, Oxidative stress

Received: 23 February 2021

Revised: 29 May 2021

Accepted: 02 June 2021

How to Cite This Article: Saoudi M, Rahmouni F, El Aroui M, Boudaya M, Jamoussi K, Kallel C, et al. Evaluation of *Urtica dioica* Extract as a Protective Agent against Hepatic and Renal Toxicity Induced by Insecticides. Int J Vet Res Allied Sci. 2021;1(1):19-31.

Introduction

Pesticides are lipophilic substances known for their neurotoxic effects and relatively low toxicity in mammals [1-5]. Their widespread use in agriculture has led to significant environmental contamination, contributing to various health issues. Exposure to different pesticide classes, including organochlorines (OCs), organophosphorus (OP), carbamates, and pyrethroids, has been associated with a range of adverse effects, including neurological disorders, carcinogenicity, respiratory complications, dermatological conditions, and reproductive abnormalities [6]. Among these, pyrethroids have been reported to cause alterations in hematologic, biochemical, and reproductive parameters [7].

Deltamethrin (DLM), a type II pyrethroid, and chlorpyrifos (CPF), an organophosphorus insecticide, belong to distinct pesticide classes but are both well-documented for their harmful effects [8]. DLM is widely utilized in agriculture as well as in household applications, with studies highlighting its immunotoxic and genotoxic impacts on mammalian species [9]. Meanwhile, CPF has been implicated in oxidative stress, inflammation, and apoptosis [10]. Due to its toxicological concerns, CPF usage was restricted in the United States in 2002 [8].

For centuries, medicinal plants have played a crucial role in traditional medicine, primarily due to their antioxidant properties, which help mitigate oxidative damage [11]. *Urtica dioica* (*U. dioica*) is one such plant, known for its therapeutic applications. Research has demonstrated its efficacy in treating nasal and menstrual hemorrhages, nephritis, anemia, and hematuria, as well as its blood-purifying properties. Additionally, it has been investigated for its potential benefits in managing diabetes, atherosclerosis, cardiovascular diseases, and prostate cancer [12]. *U. dioica* is also widely used in traditional medicine for conditions such as allergies, renal stones, burns, internal bleeding, and diabetes [13]. In Turkey and Iran, it has been employed for alleviating stomachaches, rheumatic pain, colds, and coughs [14], while its application extends to hypertension, allergic rhinitis, and cardiovascular diseases [15]. The plant's diuretic properties contribute to blood pressure reduction by lowering vascular tension [16]. Moreover, studies have reported that the aqueous extract of *U. dioica* exhibits hypoglycemic effects, and the hydroalcoholic extract of its leaves has been shown to enhance insulin secretion in rats [17].

Given these pharmacological properties, the present study aims to evaluate the protective potential of *U. dioica* extract against DLM- and CPF-induced hepatotoxicity, nephrotoxicity, and rats' oxidative stress.

Materials and Methods

Preparation of U. dioica extract

Fresh leaves of *U. dioica* were air-dried at 20 °C for one week under laboratory conditions. A total of 10 g of the dried leaf powder was then boiled in 100 ml of distilled water for twenty minutes, with intermittent stirring. The resulting decoction and the obtained extract underwent lyophilization for 48 hours. The lyophilized product was subsequently stored at 4 °C for further use.

Quantification of total polyphenolic content

The Folin-Ciocalteu method, as described by Wolfe *et al.* [18], was employed to determine the total phenolic content, with modifications for microscale analysis. A 10 µl aliquot of the diluted extract solution was mixed with 50 µl of Folin-Ciocalteu reagent and allowed to react for 5 minutes. Subsequently, 150 µl of 20% Na₂CO₃ was introduced, followed by additional shaking for 1 minute. The final volume was adjusted to 790 µl using distilled water. After an incubation period of 90 minutes, the absorbance was measured at 760 nm using a spectrophotometer. A calibration curve was generated with gallic acid as the reference standard, and the total phenolic content was displayed as mg of gallic acid equivalent per gram of dry extract based on the linear regression equation derived from the calibration curve.

Ferric reducing antioxidant power (FRAP) assay

The reducing power of a compound serves as an essential marker of its potential antioxidant activity [19]. To assess this, 0.5 ml of the extract at varying concentrations, along with the reference antioxidant ascorbic acid, was combined with one ml of a 1% potassium ferricyanide [K₃Fe(CN)₆] solution and 1 ml of phosphate buffer (0.2 M, pH = 6.6). The mixture was then incubated at 50 °C for 20 minutes. Following this, the reaction was terminated by adding 1 ml of 10% trichloroacetic acid (TCA), and the solution was centrifuged at 3000 rpm for 10 minutes. After centrifugation, 1.5 ml of the supernatant was mixed with 1.5 ml of distilled water and 0.5 ml of 0.1% ferric chloride (FeCl₃). The solution was incubated for 10 minutes, after which the absorbance was recorded at 700 nm. To standardize the comparison we used ascorbic acid.

DPPH free radical scavenging activity

The 2,2-diphenyl-1-picrylhydrazyl (DPPH) assay is one of the earliest methods used to examine the antioxidant structure-activity relationships of phenolic compounds [20]. DPPH (2,2-diphenyl-1-picrylhydrazyl) undergoes a color change from deep violet to yellow, signifying its reduction to 2,2-diphenyl-1-picrylhydrazine.

To evaluate this effect, 0.5 ml of the extract at different concentrations, along with ascorbic acid as the reference antioxidant, was mixed with 0.5 ml of DPPH dissolved in methanol. The reaction mixture was then incubated in the dark for 30 minutes. Absorbance readings were taken at 517 nm, with antioxidant activity assessed about a control solution containing absolute methanol and DPPH.

Animal selection and experimental conditions

This study utilized adult male albino Wistar rats, which were procured from the Central Pharmacy of Tunisia (SIPHAT, Tunisia). The rats were housed under controlled laboratory conditions, maintaining a 12-hour light/dark cycle, with regulated temperature and humidity levels. Throughout the study, the rats had free access to food and water (*ad libitum*). All experimental procedures were reviewed and approved by the Institutional Animal Care Committee, ensuring that the rats were handled in compliance with established institutional ethical guidelines.

Experimental design and grouping

Following a two-week acclimatization period, the rats were randomly assigned to five distinct experimental groups:

1. *Control group (Group 1)*: Rats were provided with distilled water and a standard diet *ad libitum* throughout the study.
2. *DLM/CPF group (Group 2)*: This group received a daily gavage administration of a DLM/CPF mixture (1 mg/kg/day DLM + 5 mg/kg/day CPF) for 20 consecutive days [21].
3. *Vitamin CE + DLM/CPF group (Group 3)*: Rats were treated with vitamins C and E (100 mg/kg/day for each vitamin) [22] over 20 days. Additionally, during the final 10 days, they simultaneously received the DLM/CPF mixture via gavage.
4. *U. dioica group (Group 4)*: This group was administered an aqueous extract of *U. dioica* (200 mg/kg/day) via gavage for 20 days.
5. *U. dioica + DLM/CPF group (Group 5)*: Rats were treated with the aqueous extract of *U. dioica* (200 mg/kg/day) for 20 days, while simultaneously receiving the DLM/CPF mixture (1 mg/kg/day DLM + 5 mg/kg/day CPF) during the final 10 days via gavage.

Body weight was recorded throughout the treatment period. On day 20, the animals were sacrificed by decapitation. After collecting the blood samples, we left them to clot at 20 °C. After clotting, the samples were centrifuged at 2700 g for fifteen minutes to separate the serum, which was then stored for various biochemical analyses.

The liver and kidneys were promptly removed, cut into small pieces, and washed with ice-cold saline before blotting them on filter paper. Tissue homogenates were prepared by mixing the organs in 50 mM phosphate buffer (pH = 7.4) at a 1:2 weight-to-volume ratio. The homogenates were then centrifuged at 10,000 g for 15 minutes at 4 °C using an Ultra Turrax T25 (Germany). The resulting supernatant and serum samples were aliquoted and stored at -30 °C until further analysis.

Hematological measurements

Hematological parameters were assessed, including red blood cell (RBC) count, hematocrit (Ht), mean corpuscular volume (MCV), mean corpuscular hemoglobin (MCH), hemoglobin (Hb), mean corpuscular hemoglobin concentration (MCHC), and white blood cell (WBC) count. These parameters were measured using an automated Sysmex Kx-21N system at CHU Habib Bourguiba Sfax.

Serum biochemical analysis

For serum biochemical parameters, levels of aspartate aminotransferase (ASAT), creatinine, alanine aminotransferase (ALAT), urea, and uric acid were determined using commercial kits from France. The tests were performed on an automated system at CHU Hedi Chaker, Sfax, Tunisia. The results for ASAT and ALAT were expressed in U/L, while creatinine and urea were measured in mmol/L and uric acid in $\mu\text{mol/L}$.

Protein content measurement

The protein levels in both liver and kidney tissues were quantified using the method described by Lowry *et al.* [23], with bovine serum albumin serving as the reference standard.

Assessment of advanced oxidation protein products (AOPP)

The concentration of AOPP was measured based on the procedure outlined by Kayali *et al.* [24]. In this method, 0.4 mL of tissue homogenate supernatant was mixed with 0.8 mL of Tris-buffered saline (TBS, 0.1 mol/L, pH

7.4). After two minutes, 0.1 mL of 1.16 mol/L potassium iodide and 0.2 mL of acetic acid were added. The reaction mixture's absorbance was recorded at 340 nm immediately. The AOPP concentration was obtained using the extinction coefficient ($261 \text{ cm}^{-1}\text{mM}^{-1}$) and was expressed as μmol of AOPP per milligram of protein.

Protein carbonyl content measurement

The assessment of protein carbonyl content was performed following the protocol described by Ardestani and Yazdanparast [25]. For this, 1 mL of 10 mM 2,4-dinitrophenylhydrazine (DNPH) dissolved in 2 M HCl was added to 1 mg of the sample. The mixture was incubated for 30 minutes at room temperature. Afterward, 1 mL of cold 10% trichloroacetic acid (TCA) was introduced, and the samples were centrifuged at 3000 g for 10 minutes. We washed the resulting protein pellet 3 times with a 1:1 ethanol/ethyl acetate mixture (2 mL each), then dissolved in 1 mL of 6 M guanidine hydrochloride (pH 2.3). The absorbance of the solution was measured at 370 nm. We determined the carbonyl content using the molar extinction coefficient of DNPH ($\epsilon = 2.2 \times 10^4 \text{ cm}^{-1}\text{M}^{-1}$) and expressed as nmol per mg of protein.

Lipid peroxidation (TBARS Assay)

To estimate lipid peroxidation, TBARS levels were measured, which reflect the concentration of malondialdehyde (MDA), the end product of lipid degradation, based on Yagi's method [26]. In brief, 125 μL of the supernatant was sonicated with 50 μL of Tris-buffered saline (TBS), followed by the addition of 125 μL of TCA-BHT to precipitate proteins. The mixture was centrifuged at $1000 \times g$ for 10 minutes at 4°C . To 200 μL of the supernatant, 40 μL of 0.6 M HCl and 160 μL of TBA dissolved in Tris were added. The mixture was incubated at 80°C for 10 minutes, and the absorbance was recorded at 530 nm. We calculated the concentration of TBARS using the extinction coefficient of $156 \times 10^5 \text{ mM}^{-1} \text{ cm}^{-1}$.

Conjugated diene assay

The conjugated diene levels were determined by taking 25 μL of the sample, followed by the addition of 3 mL of chloroform/methanol (2:1 v/v). After centrifugation at 3000 rpm for 5 minutes, the supernatant was removed, and the extract was dried in an oven at 45°C overnight. The residue was re-dissolved in 2 mL of methanol and the optical density (OD) was measured at 190 nm using a quartz cuvette, as described by [27].

Histopathological analysis

Tissues from the liver and kidneys were collected and preserved in a 10% formalin solution. The specimens underwent dehydration through a stepwise ethanol treatment and were then cleared with xylene. Following this, they were stained in paraffin. Sections of 5 μm thickness were cut and embedded with hematoxylin and eosin. The stained slides were observed under a microscope for any histological changes.

Statistical analysis

Results were expressed as means \pm standard error of the mean (SEM). Statistical comparisons were made using one-way ANOVA, followed by the Tukey post hoc test. A p-value of less than 0.05 was considered significant.

Results and Discussion

Total polyphenolic content and antioxidant activity of U. dioica

The *U. dioica* extract was found to have a total polyphenolic content of 712.375 μg GAE per mg of dry plant extract. The antioxidant potential of *U. dioica* was assessed through its FRAP reduction power and antiradical activity, using the DPPH free radical assay. The results showed an IC₅₀ value of 0.09 ± 1.3 for the extract and 0.07 ± 0.005 for ascorbic acid, which served as a reference (IC₅₀ = 0.07 mg/ml for ascorbic acid and 0.02 ± 0.004 mg/ml for *U. dioica*) (**Table 1**).

Table 1. Antioxidant tests of *U. dioica* by FRAP and DPPH

Parameters	IC ₅₀ of extract (mg/ml)	IC ₅₀ of ascorbic acid (mg/ml)
FRAP	0.09 ± 1.3	0.07 ± 0.05
DPPH	0.07 ± 0.005	0.02 ± 0.004

Growth curve analysis of control and treated rats

Growth assessment is an essential indicator of overall health and nutritional status. The data indicated that *U. dioica* had a protective effect in the DLM/CPF group, showing improvement compared to the group receiving only the DLM/CPF mixture. Additionally, the inclusion of vitamin CE appeared to support the restoration of body growth, in contrast to the rats receiving the DLM/CPF mix alone (**Figure 1**).

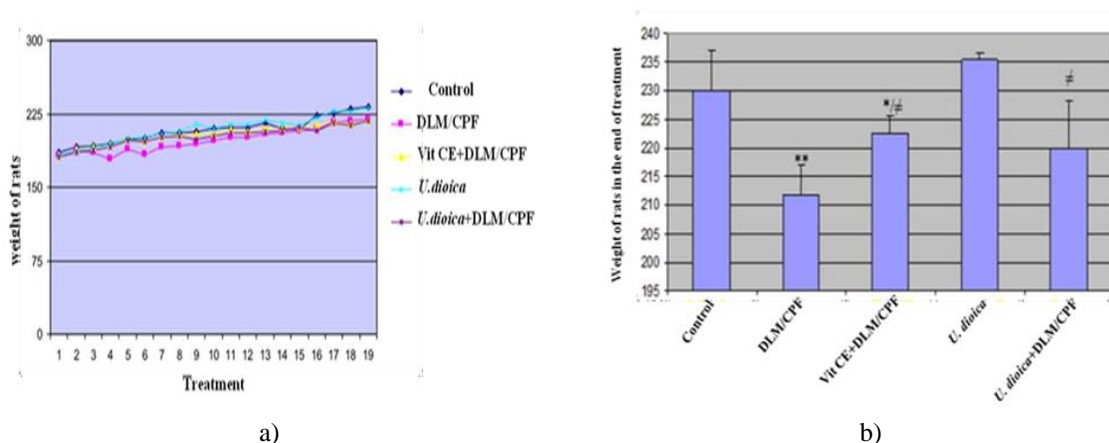


Figure 1. Growth curve and body weight in the treatment of control and treated rats

After the treatment period, the final body weight measurements revealed a significant reduction in the body weight of the DLM/CPF group compared to the control rats. The weight gain in this group was notably lower. However, the rats that were pretreated with *U. dioica* extract and vitamin CE showed a significant improvement in weight gain and body weight recovery, reversing the disturbances caused by the DLM/CPF mixture.

Hematological parameters

As shown in **Table 2**, significant reductions in red blood cell count (RBC), hemoglobin (Hb), hematocrit (Ht), mean corpuscular volume (MCV), mean corpuscular hemoglobin (MCH), mean corpuscular hemoglobin concentration (MCHC), and white blood cell count (WBC) were observed in the DLM/CPF group comparing to the control group, with decreases of -26.27%, -21.9%, -26.42%, -25.31%, 1.34%, -0.17%, and 35.66%, respectively. The groups treated with *U. dioica*+DLM/CPF or VitCE+DLM/CPF showed improvements in these parameters comparing to the DLM/CPF group, with increases of +34.36%, +32.37%, +1.43%, +3.49%, +25.39%, +16.36%, and +25.06% for *U. dioica*+DLM/CPF, and +33%, +37.14%, +5.45%, +37.1%, +26.68%, +29.23%, and +25.15% for VitCE+DLM/CPF. Importantly, no significant difference was observed between the control group and the group treated with *U. dioica* alone.

Table 2. Effects of DLM/CPF, *U. dioica*, Vit CE, and their combination (Vit CE + DLM/CPF, *U. dioica* + DLM/CPF) on some hematology parameters in blood.

Parameters and treatment	Control	DLM/CPF	Vit CE + DLM/CPF	<i>U. dioica</i>	<i>U. dioica</i> + DLM/CPF
RBC ($\times 10^6/\mu\text{L}$)	8.03 ± 0.3	$5.92 \pm 1.98^*$	$7.91 \pm 0.26^\#$	7.77 ± 0.18	$7.9 \pm 0.2^\#$
Hb (g/dl)	13.47 ± 0.22	$10.52 \pm 3.54^{**}$	$14.35 \pm 0.6^\#$	14.02 ± 0.49	$14.1 \pm 0.29^\#$
Ht (%)	43.9 ± 1.59	$32.3 \pm 10.81^*$	$44.35 \pm 1.62^\#$	42.52 ± 0.91	$43.4 \pm 0.67^\#$
MCV (fL)	54.72 ± 0.72	40.87 ± 11.8	56.05 ± 0.51	55.32 ± 0.21	54.1 ± 0.5
MCH (g/L)	17.43 ± 0.2	17.4 ± 0.18	18.35 ± 0.32	17.95 ± 0.21	17.65 ± 0.13
MCHC (g/dl)	31.93 ± 0.14	31.5 ± 0.26	32.67 ± 0.51	32.42 ± 0.31	32.6 ± 0.17
WBC ($\times 10^3/\mu\text{L}$)	14.3 ± 1.9	$9.2 \pm 3.11^*$	$13 \pm 1.93^\#$	14.75 ± 1.79	$11 \pm 0.92^\#$

Values were expressed as means \pm SEM. The number of determinations was $n = 5$; * $P \leq 0.05$ vs control *U. dioica* + DLM/CPF; Vit CE + DLM/CPF vs DLM/CPF; $^\# P \leq 0.05$

Biochemical parameters

The biochemical analysis of liver and kidney markers is presented in **Table 3**. A marked increase in serum ASAT (+11.06%), ALAT (+32.57%), ALP (+16.14%), and LDH (+13.16%) was observed in the DLM/CPF treated rats, indicating hepatotoxicity. However, pre-treatment with *U. dioica* extract significantly attenuated the rise in these liver enzymes, indicating a protective effect. In contrast, *U. dioica* alone did not result in any significant changes compared to the control group.

For renal markers, including urea, creatinine, and uric acid, no notable changes were found in the *U. dioica* only group compared to controls. The DLM/CPF group showed a significant increase in creatinine (+13.25%), urea (+9.89%), and uric acid (+24.91%). However, the groups pretreated with *U. dioica* + DLM/CPF and VitCE + DLM/CPF exhibited significant reductions in these markers, with decreases of -26%, -2%, and -14.16% for *U. dioica*+DLM/CPF, and -4%, -9.71%, and -41.61% for VitCE+DLM/CPF, respectively.

Notably, the antioxidant properties of *U. dioica* extract played a role in mitigating the toxicity removed by the DLM/CPF mixture.

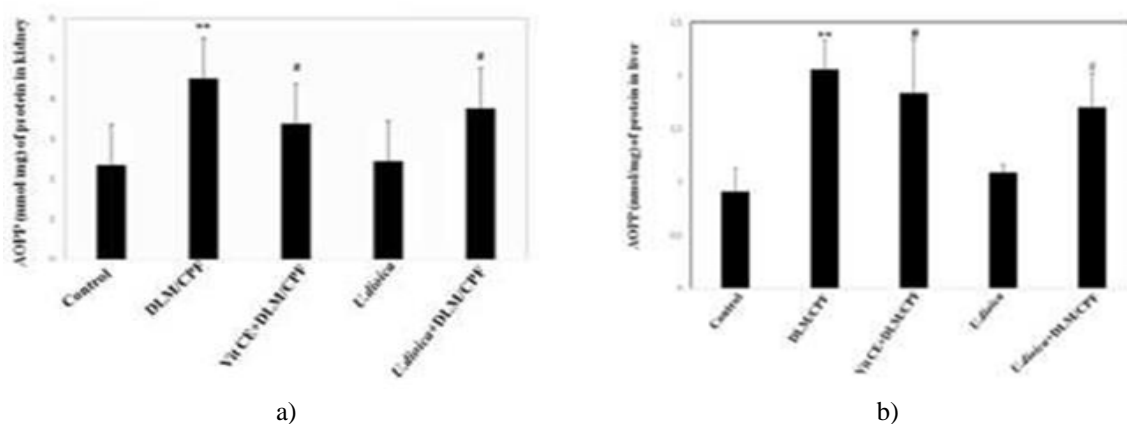
Table 3. Effects of DLM/CPF, *U. dioica*, Vit CE and their combination (Vit CE + DLM/CPF, *U. dioica* + DLM/CPF) on serum liver and kidney of control and treated rats

Parameters & treatment	Control	DLM/CPF	VitCE + DLM/CPF	<i>U. dioica</i>	<i>U. dioica</i> + DLM/CPF
ASAT (U/L)	338.33 ± 12.28	375.75 ± 28.57*	338.2 ± 41.55#	349 ± 14.65	329.66 ± 8.85#
ALAT (U/L)	88.5 ± 2.26	117.33 ± 3.23**	133.5 ± 2.84#	101.6 ± 4.34	105.5 ± 4.11#
ALP (U/L)	176.5 ± 10.89	205 ± 4.91*	165.66 ± 9.63#	166.25 ± 7.38	180 ± 5.07#
LDH (U/L)	3100.33 ± 64.4	3508 ± 10.6*	2628 ± 342.94##	3043 ± 296.11	2890 ± 190.87##
Creatinin (μmol/L)	17.66 ± 0.28	20 ± 0.7*	19.2 ± 2.07	19.66 ± 0.28	14.8 ± 0.89##
urea (mmol/L)	6.37 ± 0.19	7 ± 0.1*	6.32 ± 0.31#	6.1 ± 0.14	6.86 ± 0.16
Uric acid (μmol/L)	96.33 ± 1.52	120.33 ± 1.89*	70.25 ± 10.11##	98.66 ± 2.3	103 ± 3.46#

Values were expressed as means ± SEM. The number of determinations was n = 5 ; * $P \leq 0.05$; ** $P \leq 0.01$ vs control *U. dioica* + LM/CPF ; Vit CE + DLM/CPF vs DLM/CPF : # $P \leq 0.05$; ## $P \leq 0.01$

Assessment of protein oxidation: AOPP and CP levels

Administration of DLM/CPF led to a notable increase in the levels of AOPP and CP in both the liver and kidneys compared to the control group. However, these levels were significantly reduced in rats pretreated with *U. dioica* + DLM/CPF or VitCE + DLM/CPF when compared to the DLM/CPF only group. No significant difference was observed between the *U. dioica* treatment group and the control group, as illustrated in **Figure 2**.



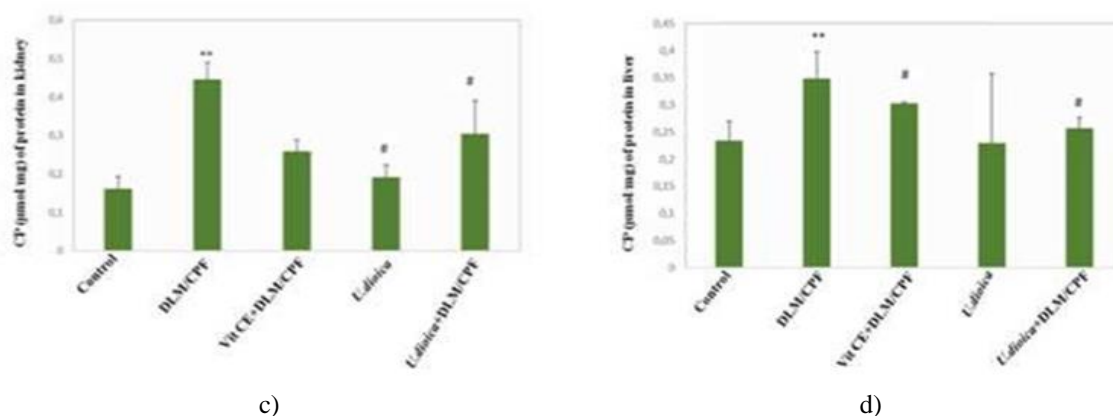


Figure 2. Effects of DLM/CPF, *U. dioica*, Vit CE and their combination (Vit CE + DLM/CPF, *U. dioica* + DLM/CPF) on advanced oxidation of protein products (AOPP) and carbonyl protein (CP) in liver and kidney of control and experimental rats

Values were expressed as means \pm SEM. The number of determinations was $n = 5$; * $P \leq 0.05$ vs control *U. dioica* + DLM/CPF; # $P \leq 0.05$ vs DLM/CPF

Lipid oxidation estimation: TBARS and CD levels

A significant rise in the levels of TBARS and CD was observed in the liver and kidney of rats treated with the DLM/CPF mixture, indicating that the pesticides induced lipid oxidation at both membrane and plasma levels. Supplementation with *U. dioica* extract or VitCE led to a reduction in TBARS and CD content when compared to the DLM/CPF only group. Interestingly, the *U. dioica* extract alone did not affect the TBARS and CD levels, as shown in **Figure 3**.

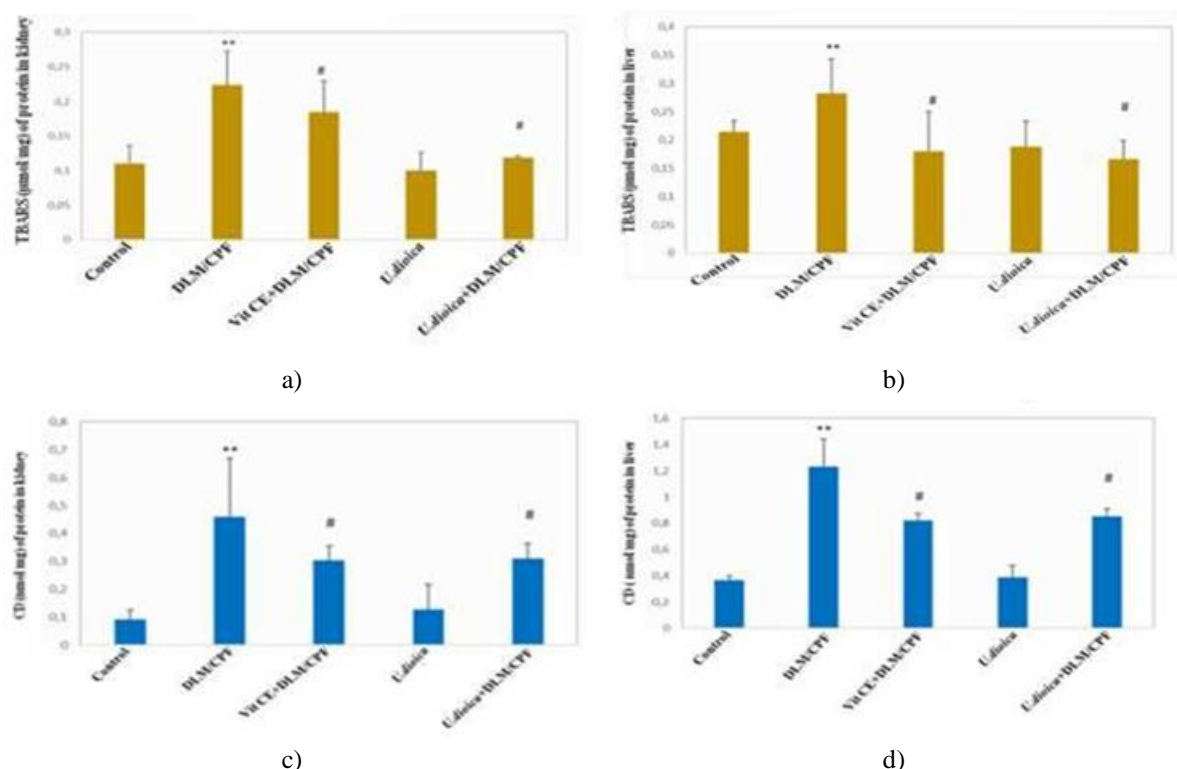


Figure 3. Effects of DLM/CPF, *U. dioica*, Vit CE and their combination (Vit CE + DLM/CPF, *U. dioica* + DLM/CPF) on thiobarbituric acid-reactive substances (TBARS) and conjugated dienes (CD) in liver and kidney of control and experimental rats

Values were expressed as means \pm SEM. The number of determinations was $n=5$; * $P \leq 0.05$ vs control *U. dioica* + DLM/CPF; # $P \leq 0.05$ vs DLM/CPF

Histopathological observations

Histological examination of the liver revealed a healthy liver structure in the control group. In contrast, significant alterations, including inflammation and leukocyte infiltration, were observed in the liver of rats treated with the DLM/CPF mixture. Pretreatment with *U. dioica* helped restore the liver's structure, mitigating the damage caused by the pesticide mixture. These findings suggest that the DLM/CPF combination has a severe hepatotoxic effect, leading to noticeable changes in liver architecture (**Figure 4**).

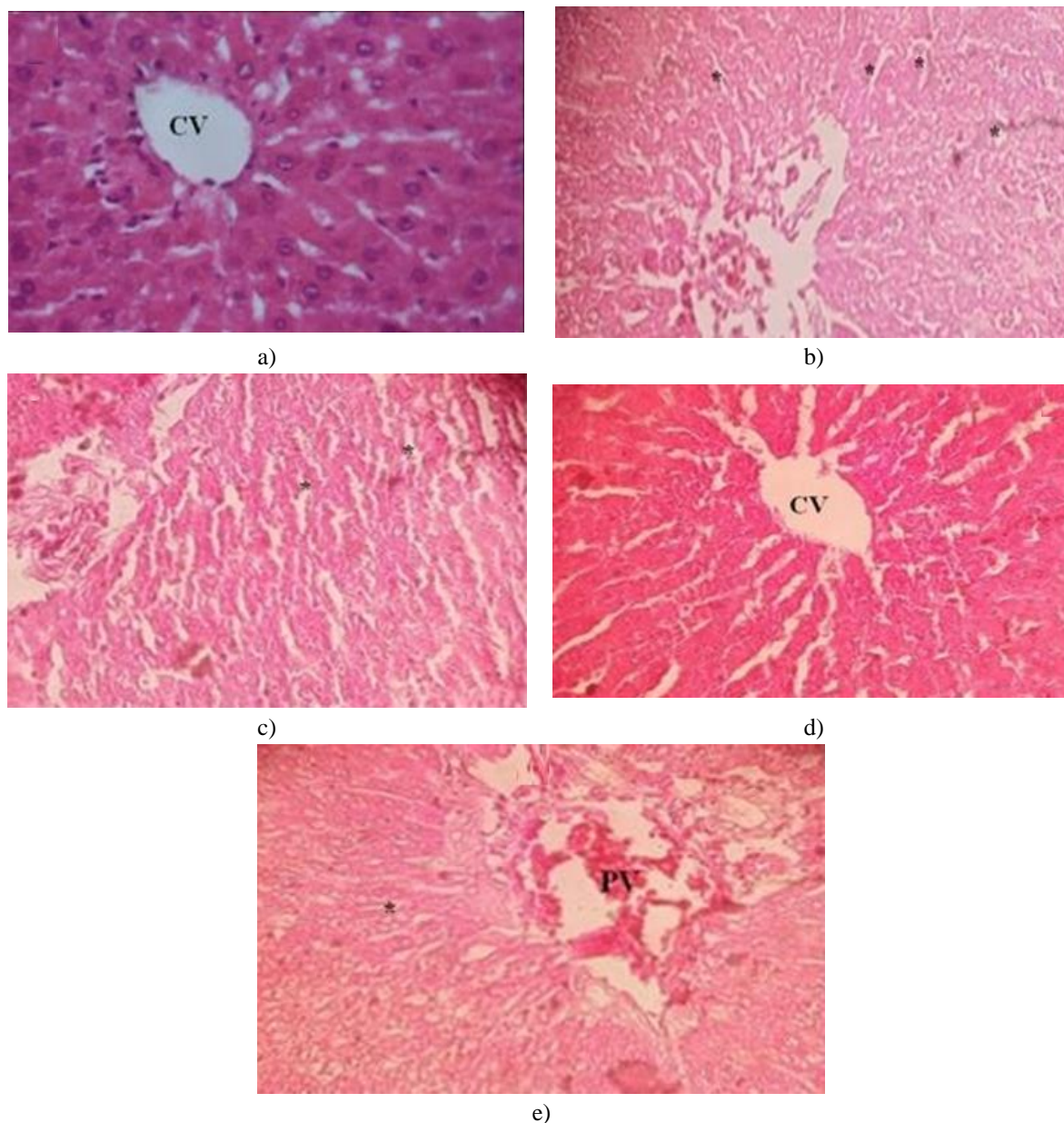


Figure 4. Representative photographs of the liver showing the protective effect of *U. dioica* on DLM/CPF-induced hepatotoxicity in rats. Control (a), rats treated with DLM/CPF (b), rats treated with the combination of Vitamins CE+DLM/CPF (c), rats treated with *U. dioica* (d), rats treated with the combination of *U. dioica* + DLM/CPF (E) CV: Centrilobular Vein; * leukocyte infiltration PV: Portal Vein

In the kidney, severe nephrotoxicity, including inflammation and epithelial detachment, was observed in rats treated with the DLM/CPF mixture. Pretreatment with *U. dioica* significantly reduced the nephrotoxic effects induced by the pesticide combination (**Figure 5**).

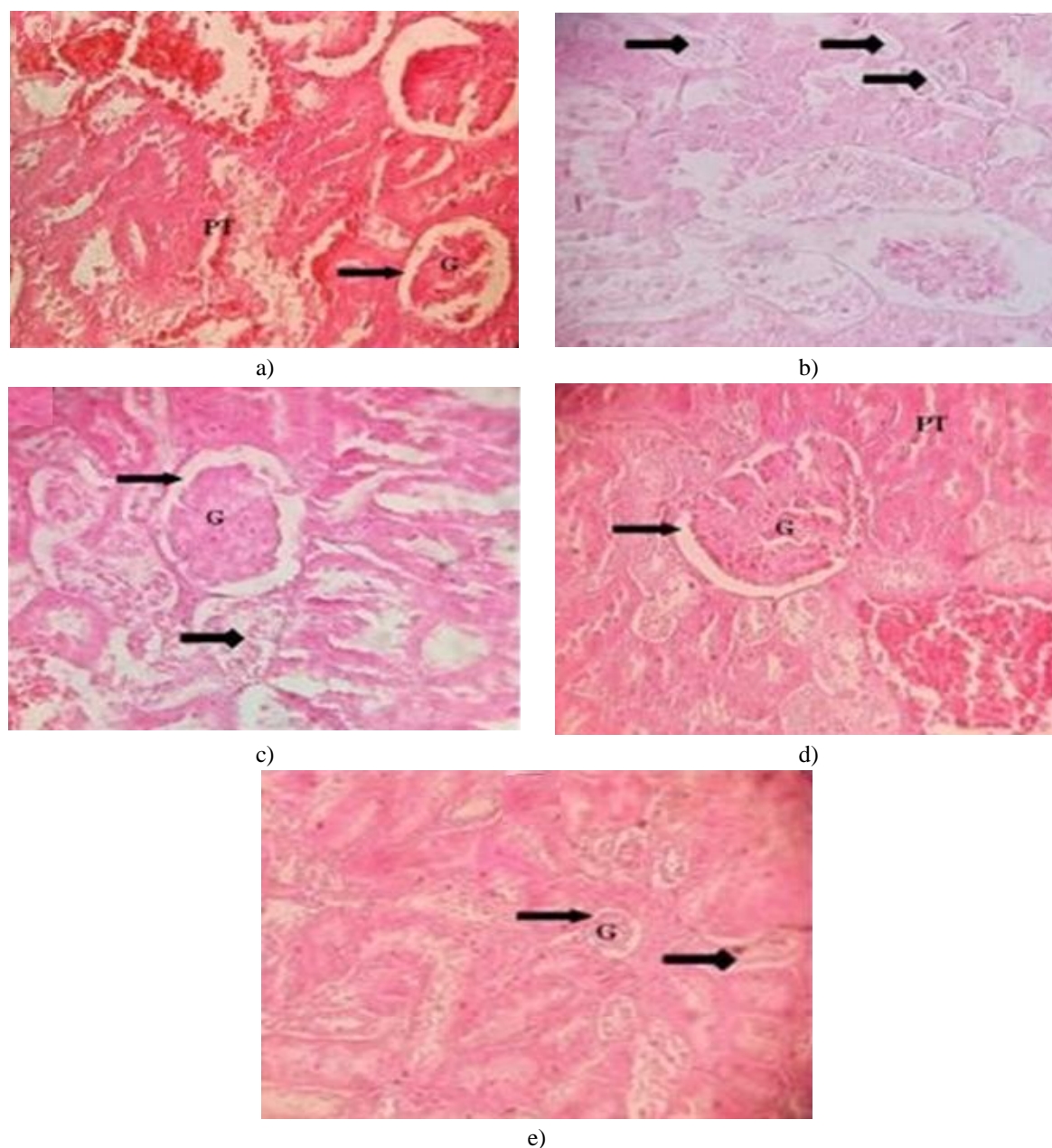


Figure 5. Representative photographs of a kidney showing the protective effect of *U. dioica* on DLM/CPF-induced nephrotoxicity in rats. Control (a), rats treated with DLM/CPF (b), rats treated with the combination of Vitamins CE +DLM/CPF (c), rats treated with *U. dioica* (d), rats treated with the combination of *U. dioica* + DLM/CPF (e) PT: Proximal Tubule; G: Glomerulus; —→DT: Distal Tubule; —◆— Leukocyte infiltration

Our findings revealed that *U. dioica* is rich in phenolic compounds and exhibits potent antioxidant activity, as demonstrated by both the FRAP and DPPH assays. Treatment with DLM/CPF led to significant reductions in hematological parameters, increases in biochemical markers, and heightened oxidative stress in both the liver and kidneys. These results were further supported by histopathological examination. The antioxidant potential of *U. dioica* would attributed to its flavonoid content, particularly chrysoeriol, along with other flavonoids and phenolic compounds [28]. These findings are consistent with the study by Vajic *et al.* [29], which reported that nettle leaves possess considerable antioxidant activity, capable of modulating blood pressure and oxidative damage in hypertensive rats. Similarly, Sadegh *et al.* [30] reported comparable levels of phenolic compounds.

In our investigation, we examined the effects of subchronic exposure to a mixture of DLM/CPF pesticides, with *U. dioica* extract used as a pretreatment. DLM/CPF administration caused a high reduction in hematological parameters, such as RBC, Hb, Ht, MCV, MCH, MCHC, and WBC, when compared to the control group. However,

pretreatment with *U. dioica* extract and Vit CE led to significant improvements in these parameters compared to the DLM/CPF group. The decrease in RBC, Hb, and Ht levels may be attributed to inhibited erythropoiesis and chemosynthesis. Furthermore, the reduction in WBC count in the DLM/CPF group could be a result of immune system suppression. Notably, *U. dioica* extracts significantly mitigated these disturbances. These findings align with Abdel-Daim *et al.* [31], which reported similar reductions in RBC and Hb levels following exposure to DLM. Numerous epidemiological studies have suggested a link between pesticide exposure and various health issues in affected populations, with evidence of carcinogenic and neurotoxic effects in animals. Our study focused on assessing the protective and antioxidant properties of *U. dioica* extract in rats treated with a pesticide mixture, evaluating the effects on liver biomarkers (e.g., ASAT, ALAT, ALP, and LDH) and kidney markers (e.g., creatinine, urea, and uric acid). The results showed a significant increase in hepatic and renal biochemical markers in the DLM/CPF group, which is indicative of tissue damage due to poisoning. However, pretreatment with the aqueous extract of *U. dioica* notably restored these markers, demonstrating its protective effect against DLM/CPF toxicity. Similarly, pretreatment with Vit CE also mitigated the toxic effects of DLM/CPF. It is noteworthy that the *U. dioica* extract contains antioxidant compounds that help reduce the overall toxicity. These results are in line with Ncir *et al.* [32], which found that deltamethrin exposure increased the activity of liver enzymes such as ASAT, ALAT, ALP, and LDH.

The present research demonstrated that the mixture of DLM/CPF caused oxidative damage in both kidney and liver tissues, as evidenced by the notable increase in AOPP and CP levels in rats exposed to these pesticides compared to controls. This increase indicates that the DLM/CPF mixture induces liver and kidney damage. Several studies have highlighted that pesticide exposure leads to alterations in protein levels. Our findings align with Hamdaoui *et al.* [33], which showed that exposure to Kalach 360 SL (an herbicide) caused ovarian protein damage, indicated by an increase in AOPP levels. Similarly, Ben Amara *et al.* [34] demonstrated that methyl thiophanate fungicide raised AOPP levels and triggered cellular toxicity in kidney and liver tissues. Additionally, Feriani *et al.* [35] found that DLM exposure caused an increase in CP levels, while Yazdinezhad *et al.* [36] reported that CPF overproduces reactive oxygen species (ROS), contributing to protein damage in liver cells. In contrast, pretreatment with either *U. dioica* extract or a Vit CE mixture significantly reduced both AOPP and CP levels, confirming the antioxidant-rich content of *U. dioica* and highlighting the protective role of Vit CE in countering the harmful effects of free radicals induced by pesticide exposure.

The current study also showed that DLM/CPF administration resulted in increased TBARS and CD levels in the liver and kidney, signaling lipid oxidation in membrane and plasma levels. These findings are consistent with previous studies [37]. Additionally, the administration of *U. dioica* extract led to a significant reduction in TBARS formation. Notably, the combination of Vit CE also decreased TBARS levels in both the liver and kidneys. These results are in line with the findings of Niki *et al.* [38], who recognized Vit CE as a potent natural antioxidant, capable of neutralizing ERO intracellularly and extracellularly [39]. The CD is a byproduct of lipid peroxidation, and its measurement serves as an indicator of oxidative stress. Our findings corroborate the study by Ncir *et al.* [32], who demonstrated that DLM exposure caused cellular damage in both the brain and kidneys. Treatment with *U. dioica* extract lowered DC levels, and the application of the Vit CE complex significantly reduced DC levels in comparison to the group exposed only to the pesticide mixture. These results echo Giray *et al.* [40], who found that vitamin E reduced CD and TBARS levels following cypermethrin exposure.

Histological evaluations further confirmed the protective effects of *U. dioica* extract and the Vit CE mixture. Our findings suggest that *U. dioica* could serve as both a preventive and therapeutic agent for oxidative liver and kidney diseases. The DLM/CPF mixture caused noticeable alterations in liver and kidney structure, including inflammation and leukocyte infiltration, compared to the control group. However, pretreatment with *U. dioica* extract or the Vit CE complex helped reverse the hepatotoxicity and nephrotoxicity induced by the pesticide mixture. These findings align with Abdou *et al.* [41], who reported that DLM exposure led to significant hepatotoxicity, characterized by necrotic changes and inflammatory cell infiltration.

Conclusion

To summarize, our findings indicate that *U. dioica* demonstrates therapeutic potential for various health issues, exhibiting significant antioxidant and antiradical properties through its polyphenol content, along with DPPH and FRAP activity. Both *U. dioica* and the combination of Vit CE contributed to a reduction in biochemical markers,

protein oxidation, and lipid peroxidation. These results support the beneficial use of *U. dioica* for health-related purposes.

Acknowledgments: None

Conflict of Interest: None

Financial Support: None

Ethics Statement: None

References

1. Rehman HU, Nawaz MA, Aman A, Baloch AH, Qader SAU. Immobilization of pectinase from *Bacillus licheniformis* KIBGE-IB21 on chitosan beads for continuous degradation of pectin polymers. *Biocatal Agric Biotechnol*. 2014;3(4):282-7.
2. Wahba HM, Mahmoud MH, El-Mehiry HF. Effect of Quinoa seeds against Cisplatin toxicity in female rats. *J Adv Pharm Educ Res*. 2019;9(3):46-52.
3. Yasmina M, Cherif A, Amel B, Randa D, Saida K, Nadira H. Influence of *Raphanussativus* seeds on sperm parameters of domestic rabbit (*Oryctolagus cuniculus*) in cadmium-induced toxicity. *J Adv Pharm Educ Res*. 2020;10(1):19-25.
4. Al-Bishri WM. Toxicity study of gold and silver nanoparticles on experimental animals. *Pharmacophore*. 2018;9(1):48-55.
5. Shatwan IM. Renoprotective effect of *Ipomoea Batatas* aqueous leaf extract on cyclosporine-induced renal toxicity in male rats. *Pharmacophore*. 2019;10(6):85-92.
6. Akoto O, Gavor S, Appah MK, Apau J. Estimation of human health risk associated with the consumption of pesticide-contaminated vegetables from Kumasi, Ghana. *Environ Monitor Assess*. 2015;187(5):244.
7. El-Demerdash FM, Yousef MI, Kedwany FS, Baghdadi HH. Role of α -tocopherol and β - carotene in ameliorating the fenvalerate-induced changes in oxidative stress, hemato-biochemical parameters, and semen quality of male rats. *J Environ Sci Health*. 2004;39(3):443-59.
8. Uchendu C, Ambali SF, Ayo JO, Esievo KAN. Bodyweight and hematological changes induced by chronic exposure to low levels of chlorpyrifos and deltamethrin combination in rats: the effect of alpha-lipoic acid. *Comp Clin Pathol*. 2018;27(5):1383-8.
9. El-Gerbed MS. Protective effect of lycopene on deltamethrin-induced histological and ultrastructural changes in kidney tissue of rats. *Toxicol Ind Health*. 2014;30(2):160-73.
10. Jowzi N, Rahimifard M, Navaei-Nigjeh M, Baeri M, Darvishi B, Rezvanfar MA, et al. Reduction of chlorpyrifos- induced toxicity in human lymphocytes by selected phosphodiesterase inhibitors. *Pest Biochem Physiol*. 2016;128(1&2):57-62.
11. Pincemail J, Bonjean K, Cayeux K, Defraigne JO. Physiological mechanisms of antioxidant defense. *Clin Nutr Metab*. 2002;16(4):233-9.
12. Ghasemi S, Moradzadeh M, Hosseini M, Beheshti F, Sadeghnia HR. Beneficial effects of *Urtica dioica* on scopolamine-induced memory impairment in rats: protection against acetylcholinesterase activity and neuronal oxidative damage. *Drug Chem Toxicol*. 2019;42(2):167-75.
13. Dar SA, Ganai FA, Yousuf AR, Balkhi MUH, Bhat TM, Sharma P. Pharmacological, and toxicological evaluation of *Urtica dioica*. *Pharm Biol*. 2013;51(2):170-80.
14. Modarresi-Chahardehi A, Ibrahim D, Fariza-Sulaiman S, Mousavi L. Screening antimicrobial activity of various extracts of *Urtica dioica*. *Rev Biol Trop*. 2012;60(4):1567-76.
15. Golalipour MJ, Ghafari S, Afshar M. Protective role of *Urtica dioica* L.(Urticaceae) extract on hepatocytes morphometric changes in STZ diabetic Wistar rats. *Turk J Gastro*. 2010;21(3):262-9.
16. Boyrie J. *Urtica Dioica* L.: a plant with multiple uses. Thesis in pharmacy. 2016;114:96-100.
17. Hailemeskel B, Fullas F. The use of *Urtica dioica* (stinging nettle) as a blood sugar lowering herb: a case report and a review of the literature. *Diabet Res Open J*. 2015;1(5):123-7.
18. Wolfe K, Wu X, Liu RH. Antioxidant activity of apple peels. *J Agric Food Chem*. 2003;51(3):609-14.

19. Oyaizu M. Studies on products of browning reactions: antioxidative activities of browning reaction prepared from glucosamine. *Jpn J Nutr.* 1986;44:307-15.
20. Kirby AJ, Schmidt RJ. The antioxidant activity of Chinese herbs for eczema and of placebo herbs—I. *J Ethnopharmacol.* 1997;56(2):103-8.
21. Tuzmen N, Candan N, Kaya E, Demiryas N. Biochemical effects of chlorpyrifos and deltamethrin on altered antioxidative defense mechanisms and lipid peroxidation in rat liver. *Cell Biochem Funct.* 2008;26(1):119-24.
22. Kalender S, Uzun FG, Durak D, Demir F, Kalender Y. Malathion-induced hepatotoxicity in rats: the effects of vitamins C and E. *Food Chem Toxicol.* 2010;48(2):633-8.
23. Lowry OH, Rosebrough NJ, Farr AL, Randall RJ. Protein measurement with the Folin phenol reagent. *J Biol Chem.* 1951;193(1):265-75.
24. Kayali R, Çakatay U, Akçay T, Altuğ T. Effect of alpha-lipoic acid supplementation on markers of protein oxidation in post-mitotic tissues of aging rat. *Cell Biochem Funct.* 2006;24(1):79-85.
25. Ardestani A, Yazdanparast R. Antioxidant and free radical scavenging potential of *Achillea* *Santolina* extracts. *Food Chem.* 2007;104(1):21-9.
26. Yagi K. A simple fluorometric assay for lipoperoxide in blood plasma. *Biochem Med.* 1976;15(2):212-6.
27. Slater TF. Overview of methods used for detecting lipid peroxidation. In *Methods in enzymology* 1984 Jan 1 (Vol. 105, pp. 283-293). Academic Press.
28. Khan AS, Yu S, Liu H. Deformation induced anisotropic responses of Ti–6Al–4V alloy Part II: a strain rate and temperature- dependent anisotropic yield criterion. *Int J Plast.* 2012;38:14-26.
29. Vajic UJ, Grujic-Milanovic J, Miloradovic Z, Jovovic D, Ivanov M, Karanovic, D, et al. *Urtica dioica* L. leaf extract modulates blood pressure and oxidative stress in spontaneously hypertensive rats. *Phytomedicine.* 2018;46:39-45.
30. Mohajer S, Mat Taha R, Mohajer M, Khorasani Esmaeili A. Micropropagation of bioencapsulation and ultrastructural features of sainfoin (*Onobrychis viciifolia*) grown in vivo and in vitro. *Sci World J.* 2014;1:64-73.
31. Abdel-Daim MM, Abd Eldaim MA, Mahmoud MM. *Trigonella foenum-graecum* protection against deltamethrin-induced toxic effects on haematological, biochemical, and oxidative stress parameters in rats. *Can J Physiol Pharmacol.* 2014;92(8):679-85.
32. Ncir M, Saoudi M, Sellami H, Rahmouni F, Lahyani A, Makni Ayadi F, et al. In vitro and in vivo studies of *Allium sativum* extract against deltamethrin-induced oxidative stress in rats brain and kidney. *Arch Physiol Biochem.* 2018;124(3):207-17.
33. Hamdaoui L, Naifar M, Rahmouni F, Harrabi B, Ayadi F, Sahnoun Z, et al. Subchronic exposure to kalach 360 SL-induced endocrine disruption and ovary damage in female rats. *Arch Physiol Biochem.* 2018;124(1):27-34.
34. Ibtissem BA, Hajer BS, Ahmed H, Awatef E, Choumous K, Ons B. Oxidative stress, and histopathological changes induced by methylthiophanate, a systemic fungicide, in blood, liver, and kidney of adult rats. *Afr Health Sci.* 2017;17(1):154-63.
35. Feriani A, del Mar Contreras M, Talhaoui N, Gómez-Caravaca AM, Taamalli A, Segura- Carretero A. Protective effect of *Globularia alypum* leaves against deltamethrin-induced nephrotoxicity in rats and determination of its bioactive compounds using high- performance liquid chromatography coupled with electrospray ionization tandem quadrupole–time-of-flight mass spectrometry. *J Funct Foods.* 2017;32:139-48.
36. Yazdinezhad A, Abbasian M, Hojjat Hosseini S, Naserzadeh P, Agh-Atabay AH, Hosseini MJ. Protective effects of *Ziziphora tenuior* extract against chlorpyrifos induced liver and lung toxicity in rat: mechanistic approaches in subchronic study. *Environ Toxicol.* 2017;32(9):2191-202.
37. Nahid P, Dorman SE, Alipanah N, Barry PM, Brozek JL, Cattamanchi A. Official American thoracic society/centers for disease control and prevention/infectious diseases society of America clinical practice guidelines: treatment of drug-susceptible tuberculosis. *Clin Infect Dis.* 2016;63(7):e147-95.
38. Niki E. Role of vitamin E as a lipid-soluble peroxy radical scavenger: in vitro and in vivo evidence. *Free Radiol Biol Med.* 2014;66:3-12.
39. Birben E, Sahiner UM, Sackesen C, Erzurum S, Kalayci O. Oxidative stress and antioxidant defense. *World Allergy Organ J.* 2012;5(1):9-19.

40. Giray B, Gürbay A, Hincal F. Cypermethrin-induced oxidative stress in rat brain and liver is prevented by vitamin E or allopurinol. *Toxicol Lett.* 2001;118(3):139-46.
41. Abdou RH, Abdel-Daim MM. Alpha-lipoic acid improves acute deltamethrin-induced toxicity in rats. *Can J Physiol Pharmacol.* 2014;92(9):773-9.